

CT-guided cryoablation of both breast cancer and lymph node axillary metastasis

C. Pusceddu¹, G. Capobianco², F. Meloni³, E. Valle⁴, S. Dessole², P.L. Cherchi², G.B. Meloni³

¹Department of Radio-Oncology, Oncological Hospital, Cagliari

²Gynecologic and Obstetric Clinic, University of Sassari, Sassari

³Institute of Radiology, University of Sassari, Sassari

⁴Department of Oncology, Oncological Hospital, Cagliari (Italy)

Summary

Breast conservation is a major goal of cancer treatment. Many different minimally invasive options have been considered such as cryoablation. This technique is the best visualized of all ablation techniques due to the phase change during ice formation. We describe a case of breast cancer with lymph node axillary metastasis treated by CT-guided cryoablation. Cryoablation may have unique benefits for cost-effective outpatient breast cancer therapy using only local anesthesia and/or mild sedation.

Key words: Cryoablation; Breast; Lymph node axillary metastases.

Introduction

Breast conservation is a major goal of cancer treatment, and local excision (i.e., lumpectomy) followed by radiation therapy is the current standard of care [1]. However, 35% of patients who undergo lumpectomy note serious breast asymmetry, and morbidity rates of 11% for bleeding and 3% for infections [2]. Therefore, many different minimally invasive options have been considered such as cryoablation. This technique is the best visualized of all ablation techniques due to the phase change during ice formation. The margins of low-density, solid ice are well seen with US, CT, and MR imaging [3, 4]. We herein report the case of a patient with breast cancer with lymph node axillary metastasis treated by CT-guided cryoablation.

Case Report

A 57-year-old Caucasian woman presented to our Breast Center with left breast cancer and metastasis (cT2, N1, M1 bone), negative for hormonal receptors, (HER2+++), Ki67 30%). In 2006 the woman underwent medical treatment by chemotherapy with good clinical local response and no progression of disease. In May 2009, because of relapse of disease in the left breast and axillary lymph node (Figure 1a; 3a), we proposed a standard surgical treatment but the woman refused.

Thus we performed CT-guided cryoablation of the left mass (3.2 cm) in the superior internal quadrant and of the omolateral axillary lymph node (2 cm).

For local anesthesia, 2-5 ml of 1% lidocaine was injected into the deeper tissues proximal to the mass along the expected course of the cryoprobe. Thereafter, two cryoprobes were percutaneously inserted through the skin opening, with CT-guidance, into the center of the breast mass and of the lymph node, respectively (Figure 2a-b). A tabletop argon gas-based cryoab-

lation system (Galil Medical, Yokneam, Israel), which was designed to create probe temperatures of -180°C , was used to treat the lesions in an outpatient setting. The cryoablation procedure consisted of a double-freeze-thaw protocol. Cell destruction is caused by not only the freezing of the cell but also the thawing of the cell. A double-freeze-thaw cycle has been reported to increase the extent of cell damage and to ensure complete cell destruction at final freezing temperatures [5].

Complete ablation of the breast and lymph node lesions was obtained.

CT follow-up after one month (Figures 1b-3b) demonstrated the lack of enhancement of the breast lesion and lymph node lesion: this finding indicated complete destruction of the cancer. After eight months (Figures 1c-3c), the patient was free from local disease.

Discussion

A lumpectomy, while an important improvement over mastectomy, is still an invasive procedure, with potentially undesirable cosmetic results. For this reason, there has been interest in less invasive percutaneous ablation.

Cryoablation is tissue destruction by using controlled freezing and has been investigated as an alternative to conventional surgery in the treatment of benign and malignant neoplasms [5-7].

To our knowledge, this case is very rare because the woman had metastasis and refused the standard surgery after relapse of disease. However, cryoablation permitted the destruction of the breast and axillary lesions. Today, the patient is free from local disease.

CT-guided cryoablation of both breast and lymph node metastasis in our case was a safe and feasible technique. The lack of complications is promising. Cosmetic outcome is very positive. The reduced morbidity and mortality compared with those of surgery and those of nonsurgical options in patients who are not candidates for surgical therapy are also advantages.

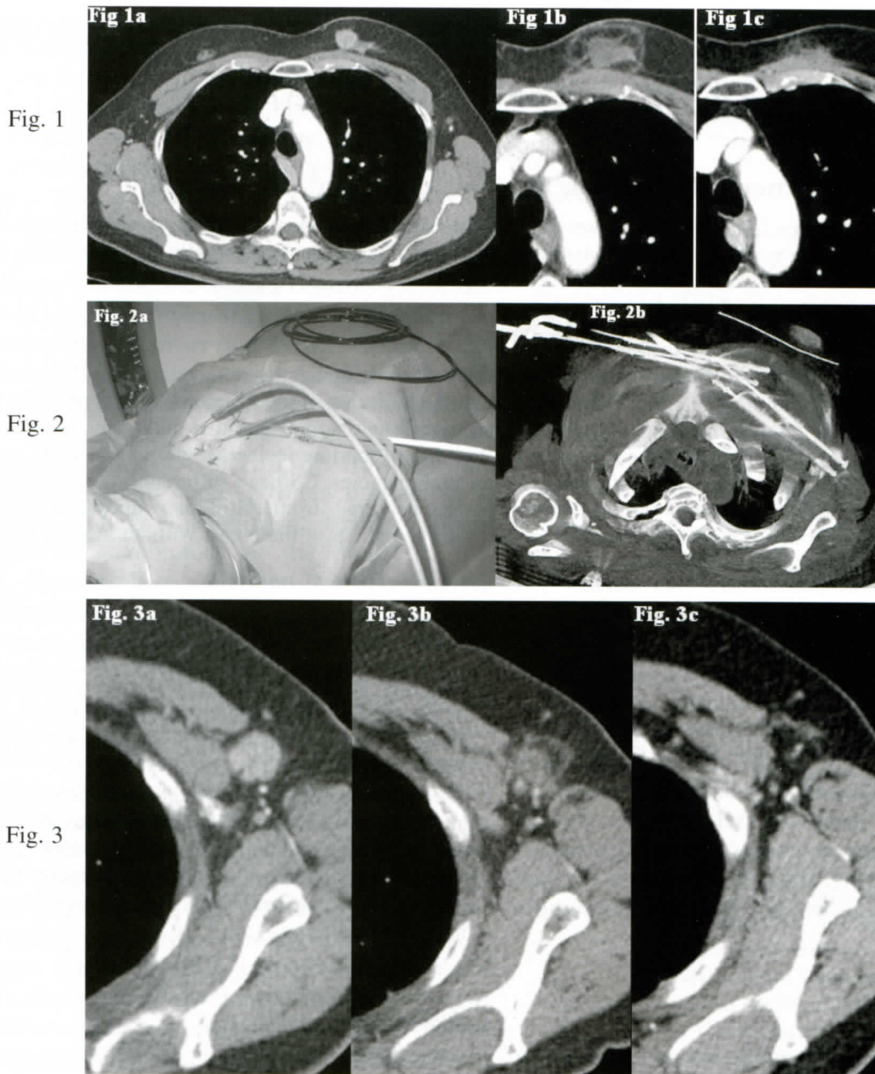


Fig. 1

Fig. 2

Fig. 3

Figure 1. — CT shows left breast cancer (a). CT of the left breast, performed after 1 month (b) and 8 months (c), showing lack of enhancement.

Figure 2. — Photo of the two cryoprobes percutaneously inserted through the skin opening (a). Two cryoprobes percutaneously inserted through the skin opening, with CT-guidance, into the center of the breast mass and lymph node (b).

Figure 3. — CT shows axillary lymph node metastasis (a). CT of the lymph node, performed after 1 month (b) and 8 months (c), showing lack of enhancement.

References

- [1] Littrup P.J., Jallad B., Chandiwala-Mody P., D'Agostini M., Adam B.A., Bouwman D.: "Cryotherapy for breast cancer: a feasibility study without excision". *J. Vasc. Interv. Radiol.*, 2009, 20, 1329.
- [2] Van Esser S., van den Bosch M.A., van Diest P.J., Mali W.T., Borel Rinkes I.H., van Hillegersberg R.: "Minimally invasive ablative therapies for invasive breast carcinomas: an overview of current literature". *World J. Surg.*, 2007, 31, 2284.
- [3] Kaiser W.A., Pfeleiderer S.O., Baltzer P.A.: "MRI-guided interventions of the breast". *J. Magn. Reson. Imaging*, 2008, 27, 347.
- [4] Pfeleiderer S.O., Marx C., Camara O., Gajda M., Kaiser W.A.: "Ultrasound-guided, percutaneous cryotherapy of small (≤ 15 mm) breast cancers". *Invest. Radiol.*, 2005, 40, 472.
- [5] Rui J., Tatsutani K.N., Dahiya R., Rubinsky B.: "Effect of thermal variables on human breast cancer in cryosurgery". *Breast Cancer Res. Treat.*, 1999, 53, 185.

- [6] Sabel M.S., Kaufman C.S., Whitworth P., Chang H., Stocks L.H., Simmons R., Schultz M.: "Cryoablation of early-stage breast cancer: work in progress report of a multi-institutional trial". *Ann. Surg. Oncol.*, 2004, 11, 542.
- [7] Kaufman C.S., Bachman B., Littrup P.J., White M., Carolin K.A., Freeman-Gibb L. *et al.*: "Office-based ultrasound-guided cryoablation of breast fibroadenomas". *Am. J. Surg.*, 2002, 184, 394.

Address reprint requests to:
P.L. CHERCHI, M.D.
Gynecologic and Obstetric Clinic
University of Sassari
Viale San Pietro, 12
07100 Sassari (Italy)
e-mail: capobia@uniss.it